

## PATIENT

Verdell Zimmer

## SPECIES

Canine

## BREED

Brussels Griffon

## SEX

MN

## AGE

11 y

## WEIGHT

21.4 lb

## INTERPRETED BY

Keith Blass, DVM, MS,  
DACVIM (Cardiology)

## IMAGING PERFORMED BY

Andrea Nicastro, DVM,  
DACVIM

## HOSPITAL NAME

Waterway AH

## REFERRING VET

Dr. Roland

## INVOICE

## DATE

12/31/25

## PRESENTING CLINICAL SIGNS

Recheck degenerative valved disease. No current medications.

## ECHOCARDIOGRAPHIC FINDINGS

2D, M-mode, and Doppler study. This exam is compared to the one performed 1/17/25.

Left atrial size is normal. The mitral valve leaflets are mildly thickened and exhibit mild systolic prolapse. A mild to moderate jet of eccentric mitral regurgitation is present. Left ventricular dimensions are normal. Left ventricular systolic function is normal. The aorta and aortic valve are normal. Right atrial and right ventricular dimensions are normal. The tricuspid valve leaflets are very mildly thickened, and a very mild jet of tricuspid regurgitation is present. TR velocity does not suggest the presence of pulmonary hypertension. The pulmonary artery and pulmonic valve are normal. No shunting lesions are visualized. No pericardial effusion or cardiac masses are seen.

ECG during echo: Sinus arrhythmia

LA – 29.3 mm (prev. 29.3 mm)  
LVIDd – 30.6 mm (prev. 30.4 mm)  
LVIDs – 19.0 mm (prev. 19.0 mm)  
FS – 37.9% (prev. 37.5%)  
RA – 20.4 mm (prev. 21.2 mm)  
LVOT – 1.38 m/s (prev. 1.34 m/s)  
RVOT – 0.92 m/s (prev. 0.90 m/s)  
TR – 2.30 m/s

## ASSESSMENT/RECOMMENDATIONS

Degenerative mitral and tricuspid valve disease – stage B1

This examination demonstrates no progression of Verdell's valvular diseases over the past 11 months. As such, his current risk for the development of clinical signs secondary to them, such as coughing, exercise intolerance, syncope, abdominal distension, and labored breathing, still appears to be low.

No therapy is recommended at this stage of Verdell's valvular diseases.

A recheck echocardiogram is recommended in 6 months. Thoracic radiographs are recommended if Verdell experiences respiratory clinical signs.



### PATIENT

Verdell Zimmer

### SPECIES

Canine

### BREED

Brussels Griffon

### SEX

MN

### AGE

11 y

### WEIGHT

21.4 lb

### INTERPRETED BY

Keith Blass, DVM, MS,  
DACVIM (Cardiology)

### IMAGING PERFORMED BY

Andrea Nicastro, DVM,  
DACVIM

### HOSPITAL NAME

Waterway AH

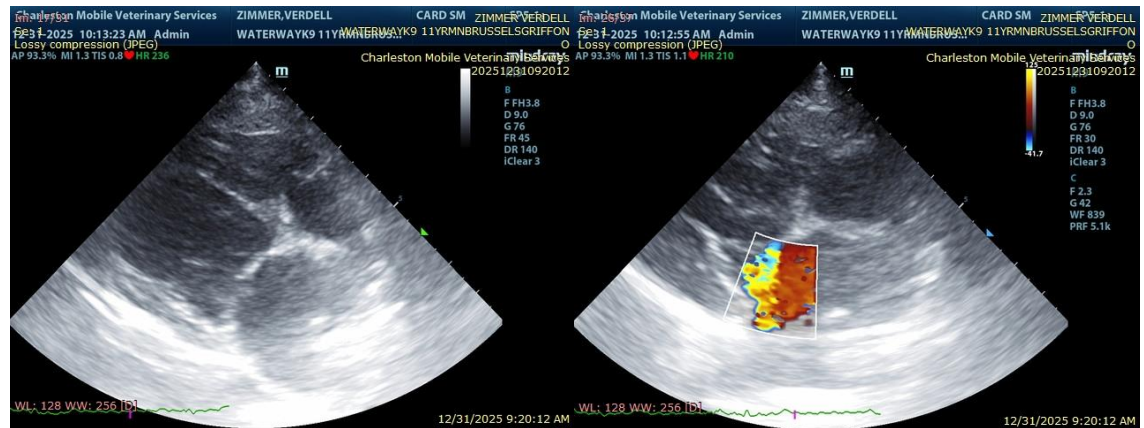
### REFERRING VET

Dr. Roland

### INVOICE

### DATE

12/31/25



The information and recommendations provided are based on the images presented by the referring veterinarian/sonographer. No evaluation can be communicated regarding pathology that was not visible in the image/video clips provided.

Thank you for this referral. If the clinical or image interpretation does not parallel your findings or if I can be of any further assistance please contact me.

Keith Blass, DVM, MS, DACVIM (Cardiology)

[info@SonoPath.com](mailto:info@SonoPath.com)